



PATIENT

Annie Ruppert

PRESENTING CLINICAL SIGNS

History: Progressive heart murmur, now grade II-III/VI. No clinical signs.

SPECIES

Canine

ECHOCARDIOGRAM FINDINGS

2D, m-mode, color flow and Doppler imaging is available.

BREED

Bichon Frise

Left ventricle: The LV diameter is increased with hyperdynamic function. LV wall thicknesses are normal.

Left atrium: The left atrium is severely dilated.

Mitral valve: The mitral valve is diffusely thickened with prolapse into the left atrial lumen. Severe eccentric mitral regurgitation with a normal velocity.

Aortic valve/Aorta: The aortic valve appears thickened with borderline increased outflow velocity; laminar flow. No aortic insufficiency.

SEX

Female Spayed

Right ventricle: Normal right ventricular diameter and morphology indicating no overt evidence of pulmonary arterial hypertension.

Right atrium: Normal RA dimension.

AGE

13 years

Tricuspid valve: The tricuspid valve appears mildly thickened with mild to moderate tricuspid regurgitation; normal velocity.

Pulmonic valve/Pulmonary artery: The pulmonic valve is normal in morphology and mobility. No pulmonic insufficiency. Normal RVOT velocity; laminar flow.

WEIGHT

17lbs

Pericardium/other: No pericardial or pleural effusion noted. No obvious cardiac masses.

Heart rhythm: ECG reveals a sinus rhythm with an average HR of 140bpm.

2-Dimensional Measurements

Doppler Measurements

INTERPRETED BY

Maggie Machen
Lamy, DVM
DACVIM (Cardiology)

Ao diam (cm)	1.3
LA diam (cm)	3.2
LA:Ao (Swe)	2.4
IVS thickness (cm)	0.7
LVID diastole (cm)	3.4
PW thickness (cm)	0.7
LVID systole (cm)	1.6
FS (%)	53

PV Vmax (m/s)	0.6
AoV Vmax (m/s)	1.2
MR Vmax (m/s)	5.7
TR Vmax (m/s)	2.7
TR PG (mmHg)	30

IMAGING

PERFORMED BY

Pamela Harrigan,
RDCS

INTERPRETATION OF THE FINDINGS

Chronic degenerative valve disease causing severe mitral and mild to moderate tricuspid regurgitation. The LA is significantly dilated indicating an elevated risk for clinical signs going forward. TR is noted with no significant elevation in pulmonary pressures. No additional concurrent issues are documented.

HOSPITAL NAME

Canton Veterinary
Clinic

With this degree of left heart changes, the risk for spontaneous congestive heart failure is elevated and cardiac supportive medications are indicated as below. A weak diuretic (spironolactone) is included given high risk for decompensation in the future even with no reported symptoms. Assessment of progression in the future will help predict long term outcome, however prognosis is guarded at this stage (late B2). Unfortunately, the patient will always be at risk for recurrent CHF, development of arrhythmias/LA tear, syncope and/or sudden death in the future.

REFERRING VET

Dr. Belisle

INVOICE

29527

DATE

3/10/23

RECOMMENDATIONS

- Institute Pimobendan 0.3mg/kg PO q12h.



PATIENT

Annie Ruppert

SPECIES

Canine

BREED

Bichon Frise

SEX

Female Spayed

AGE

13 years

WEIGHT

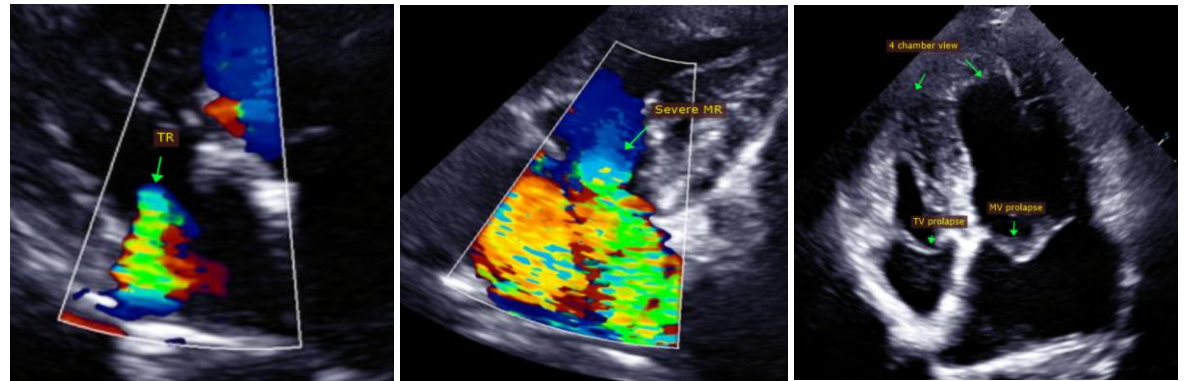
17lbs

- Institute ACE-I (benazepril or enalapril) 0.5mg/kg PO q12h.
- Institute spironolactone 1-2mg/kg PO q12h.
- Close monitoring for development of associated clinical signs (development of a cough, labored breathing, exercise intolerance or worsening collapse episodes) is recommended. Monitoring of sleeping breathing rates is recommended as the best way to screen for CHF at home.
- Omega fatty acid supplementation and mild salt restriction may be of some long-term benefit. Mild activity restriction is advised.
- Elective anesthesia is not advised, as there is high risk for complication. If necessary, cardiac protective drug choices (opioid/benzodiazepine premedication, propofol or alfaxalone induction, iso or sevoflurane gas) are recommended. Pre-oxygenate for 5-10 minutes prior to induction and recover in O2 cage. Monitor for arrhythmias, hypotension, and hypoxia both intra and post-operatively and intervene as necessary. Moderate IV fluid restriction is recommended to avoid fluid overload. Avoid heart rate stimulating drugs such as atropine unless clinically indicated.

PLAN

- A renal panel is recommended in 1-2 weeks, then every 3-4 months lifelong.
- Recommend conservative monitoring with a recheck echocardiogram in 6 months, sooner if any development of clinical signs.

IMAGES



INTERPRETED BY

Maggie Machen Lamy, DVM
 DACVIM (Cardiology)

IMAGING PERFORMED BY

Pamela Harrigan, RDCS

HOSPITAL NAME

Canton Veterinary Clinic

The information and recommendations provided are based on the images presented by the referring veterinarian. No evaluation can be communicated regarding pathology that was not visible in the image/video clips provided.

REFERRING VET

Dr. Belisle

Thank you for this referral. This report was generated using transcription software, and minor dictation errors may be present. If the clinical or image interpretation does not parallel your findings or if I can be of any further assistance, please contact me.

INVOICE

29527

Maggie Machen Lamy, DVM
 Diplomate of the American College of Veterinary Internal Medicine (Cardiology)
 info@sonopath.com

DATE

3/10/23

Echocardiogram performed by: Pamela Harrigan, RDCS
 Pet Animal Ultrasound Service (4paus.com)